

Computerized Detection of Cemento-Enamel Junctions in Digitized Dental Radiographs

Robert M. Haralick, Dept.of.EE, University of Washington , Seattle, WA 98195.
Visvanathan Ramesh, Dept.of.EE, University of Washington, Seattle, WA 98195.
Ernest Hausmann, Dept.of.Oral Biology, SUNY Buffalo, Buffalo, NY 14214.
Kristin Allen, Dept.of.Oral Biology, SUNY Buffalo, Buffalo, NY 14214.

ABSTRACT

This paper presents a mathematical morphology algorithm for the detection of the cemento-enamel junction on dental radiographs to determine anatomical crest level.

1. Introduction.

Alveolar crest level as seen on dental radiographs is an indicator of a patient's past history of destructive periodontal disease and change in the crest level has been used to monitor disease activity [1,2]. The cemento-enamel junction (cej) has been used as a fixed landmark in order to determine the anatomical crest level from a radiograph. and different criteria have been used for identification of crest and cej on radiographs [3,4,5]. This paper discusses a morphological approach to accurately locate cej's in a dental radiograph. Mathematical morphology is an approach to image processing based on set theoretic concepts of shape [6,7,8]. For a detailed review of morphological techniques the reader is referred to Haralick [8].

2. Background and Medical Significance

Radiographic crest levels has often been expressed as a ratio of the bone height to root length [4,5] and it was believed that this would correct for projection distortion in the radiograph. It was shown in [5] by utilizing intraoral radiographs of human skulls taken at various known vertical angulations that the crest level can be expressed as a distance between cej and the crest. The crest level so obtained is as accurate as the ratio of bone height to root length [5]. A sequence of morphological operations used to accurately determine the location of the cej is given below.

3. CEJ extraction using mathematical morphology

3.1 Basic Morphological Operators.

An image can be represented by a set of pixels. The morphologic operators work with two images: the

original image (data to be analyzed) and a structuring element, which is analogous to the kernel of a convolution operation. If A is a set of points representing the binary pixels with value 1 and B is a set of points representing the binary pixels with value 1 in the structuring element, then the dilation of A by B is defined by:

$$A \oplus B = \bigcup_{a \in A} \{b + a | b \in B\}$$

The erosion of A by B is given by:

$$A \ominus B = \{p | B + p \subseteq A\}$$

For a gray scale image, the dilation of a gray-scale image f by a gray scale structuring element b is denoted by d and is defined by:

$$f \oplus b = \max_{i,j} (f(r - i, c - j) + b(i, j))$$

where the maximum is taken all over (i, j) in the domain of b such that $(r - i, c - j)$ is in the domain of f . The domain of d is the dilation of the domain of f with the domain of b . The erosion of a gray scale image f by a structuring element b is denoted by e and is given by:

$$f \ominus b = \min_{i,j} (f(r + i, c + j) - b(i, j))$$

where the minimum is taken over all (i, j) in the domain of b . The domain of e is the domain of f eroded by the domain of b .

The opening of image an B by a structuring element K is denoted by $\bar{B} \circ K$ and is defined as: $\bar{B} \circ K = (\bar{B} \ominus K) \oplus K$. The closing of image an B by a structuring element K is denoted by $B \bullet K$ and is defined as: $B \bullet K = (B \oplus K) \ominus K$. The interested reader is referred to [9] for details of the properties of these two morphological operations and their gray scale implementations.

3.2 Problem definition

The problem consists of determining the exact position of the cej in a set of dental images. It can be seen from figure 1 that the gray tone surface in the region of interest can be best characterized by a hill along the column in the image, if the teeth are oriented vertically. A one dimensional plot of the underlying gray tone function in the image reveals this. Figure 1 gives a plot of the image gray tone values.

3.3 Solution

It can be seen that the input image has the following features:

1. Within each tooth the gray tone is approximately constant. That is, the gray values are approximately constant within the region.
2. The boundary of a single tooth is typically characterized by a zone of sharp intensity change
3. Fillings or metal caps on teeth result in a bright zone and they have to be taken care of when the processing is done.
4. The cej is close to the gum region in between the teeth. This region is typically dark.

3.4 Basic Algorithm

The algorithm can be broken down into two parts, namely:

1. Finding the gray tone hill oriented along the column axis. Note that it is assumed that the teeth are approximately vertical in the image.
2. Extracting only the corner (cej) from the output image obtained from step 1.

3.4.1 Stage 1

The portion of the image having the characteristics similar to a sharp gray tone hill is extracted by the sequence of operations given below. Let I_1 denote the input image. The first step involves removing any small gray tone pits in the image by performing a closing operation. The closing is done using a disk as structuring element. The radius r_1 of the structuring element used should be so chosen that small black spots in the image are removed and the output image I_2 is a smoothed version of the input.

The smoothed image (I_2) is then opened using a cylindrical structural element. The reason for using a cylindrical structural element is mainly because each tooth can be considered to be of a rectangular cross-section with protrusions in the sides which are nothing but triangles. The main assumption here is that the teeth are all oriented along the column direction. Let K denote the cylindrical structuring element used for the opening operation. The portion of the image with constant gray tone surface is open under K . Hence the opening operation results in an image (I_3) with gray tone hills removed. Taking the residue $I_2 - I_3$, gives an image with small bright regions, in which our region of interest is also one. Thresholding the residue image gives image I_4 which consists of our region of interest plus some other unwanted information.

3.4.2 Stage 2

The output from stage 1 consists of triangular regions whose tips denote the interesting points we need. If we locate the gum region in between teeth and then dilate that region so that the dilated region just encloses the corner pixels we need then the problem is solved. Another approach would be to threshold the original image such that the dark background pixels are labeled 1 and other pixels are labeled as zero. Then we can dilate the resulting image with a disk structuring element and then *AND* the result with the output from stage 1.

Both of these approaches were found to be satisfactory. However, some preprocessing was necessary in order to remove noise and other extraneous information due to other artifacts in the image. Hence the actual algorithm consisted of:

1. Doing some preprocessing to get rid of noise and other artifacts. The basic idea used here was that the regions we are interested are long thin triangles with the longer side in the row direction. An opening with a box structuring element of small width (W) and large height (H) is done in order to remove all artifacts.
2. Opening the resulting image I_5 with a box structuring element (B) of small width (usually 2 pixels wide) and obtaining the residue $I_6 = (I_5 - I_5 \circ B)$. The residue image (I_6) consists of the corners we need.
3. Thresholding the original input image such that dark background pixels are labeled as 1's and then dilating the resulting image with a disk structuring element of small radius to get the image I_7 .
4. *AND*ing the images I_7 and I_6 to get the necessary corners.

Note that step 3 can be modified such that we actually locate the gum regions in the image and then perform a dilation operation and get I_7 .

4. Results and Conclusion.

The dental images used for the experiments were obtained by digitizing radiographs in an image analysis system which comprised of an IBM-PC/XT computer with a TARGA-8(Truvision) image board having 512 by 512 pixel resolution and 256 gray levels. The video image was acquired by means of a Cohu 4815/5000 solid state video camera and calibration of pixel size to mm was done both x and y directions since the x-pixel length and the y-pixel length were found to differ. The results of the algorithm on two dental images are given in figures 2 and 3. The extracted points of interest are highlighted by bright spots in the image. It can be seen that the algorithm performs very well and that the results are rather accurate. The accuracy of the pinpointed location of the cej is determined by several factors including the radius of the cylindrical structuring element K used in stage 1 and the width of the box structuring element B used in stage 2. The true values for the cej's were compared with the results obtained by computer and it was seen that the coordinates given by the algorithm were within ± 4 pixels. If more accuracy is desired then further processing needs to be done using only the portion of the image surrounding the marked cej's.

We have demonstrated that by employing a simple sequence of operations involving morphological openings and closings and other basic boolean operations the desired cej can be extracted accurately. It can also be seen that several choices have to be made regarding the sizes of the structuring elements used in various steps in the algorithm. Further work is needed to develop a program which highlights sites of significant change with time and staging for recommended forms of therapy for

use by dental researchers and practitioners. Also, the accuracy of such a system has to be determined.

Acknowledgements

This research was partly funded by a grant from New York State Science and Technology Foundation.

References

1. Lang,N.P., Hill,R.W., Journal of Clinical Periodontology, Vol.4, pp. 16-28, 1977.
2. Hausmann,E., Jeffcoat,M., Journal of Clinical Periodontology, Vol.15, pp. 134-136, 1988.
3. Schei,O., Waerhang,J., Loudal,A., Arno,A., Journal of Periodontology, Vol.30, pp. 7-16, 1959.
4. Bjorn,H., Halling,A., Thyberg,H., Odontal Revy, Vol.20, pp. 165-179, 1959.
5. Hausmann,E., Allen,K., Christersson,L., Genco,R., Journal of Periodontal Research, In press.
6. J.Serra, Image Analysis and Mathematical Morphology. London: Academic, 1982.
7. S.R.Sternberg, "Biomedical Image Processing," IEEE Computer Magazine, Vol. 16, Jan. 1983.
8. Haralick, Robert, Sternberg Stanley and Zhuang, Xinhua (1986) Image Analysis Using Mathematical Morphology: Part I. MVI report.

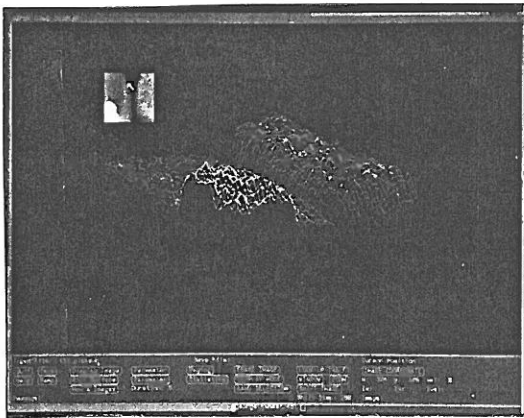


Figure 1. A portion of tooth image and its gray tone plot.

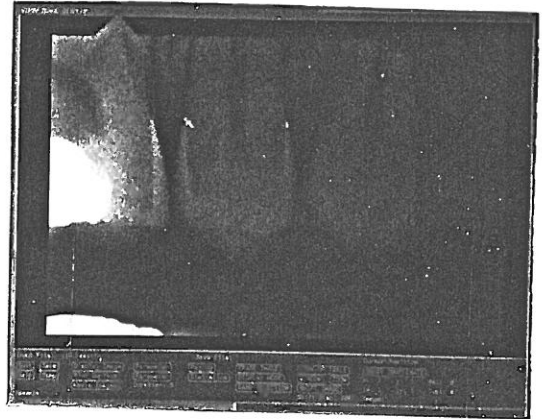


Figure 2. Tooth image with overlaid results.

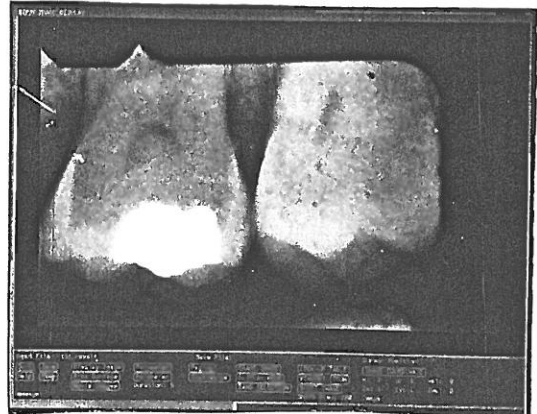


Figure 3. Tooth image with overlaid results.